

# PECULIAR ASPECTS OF INFLAMMATORY SINO-ORBITAL SYNDROME IN CHILDREN

KARIN HORVATH<sup>1</sup>, GH. MÜHLFAY<sup>2</sup>, DIANA CONSTANTINESCU<sup>3</sup>, FLORINA VULTUR<sup>4</sup>

<sup>1,3,4</sup>Oftalmologic Clinic, Tg-Mureș, <sup>2</sup>ORL Clinic, Tg-Mureș

**Keywords:** ocular orbital complications, sinusitis

**Abstract:** Purpose: the paper emphasizes an interdisciplinary pathology of sinus etiology with orbital involvement which often raises issues regarding the solving of the cases in due time. Material and method: it is reported a group of 8 children between 3 and 18 years-old, with different ophthalmologic diagnosis (orbital cellulitis, phlegmon, dacryocystitis, retrobulbar optic neuritis) but they all suffered from severe paranasal sinusitis. The management of the cases and the most efficient treatment are described. Results: at first, due to the ophthalmologic manifestation of the disease, the children usually go to the ophthalmologist, who initiates an examination strategy as well as an initial treatment. Along with the radioimagic diagnosis of a paranasal sinusitis, mostly ethmoidal in children's case, the ENT specialist takes under consideration the drainage of the sinus infection. All interventions were done by FESS method and had excellent results. Conclusions: keeping in mind that most of the time there are major emergencies lives threatening for the children, the ophthalmologist must be able to establish a probable diagnosis in due time and send the child to a paraclinical, interclinical consult (CT, ENT) qualified in solving such a case.

**Cuvinte cheie:** complicații orbitare oculare, sinuzite

**Rezumat:** Scopul lucrării: lucrarea se adresează unei patologii interdisciplinare, de etiologie sinusală cu implicație orbitală, care ridică adesea probleme în ceea ce privește rezolvarea în timp util a cazurilor. Material și metodă: se prezintă un lot de 8 copii cu vârste cuprinse între 3 și 18 ani, cu diagnostice oftalmologice diverse (celulită orbitală, flegmon, dacriocistită, nevrită optică retrobulbară), dar care prezentau cu toții sinuzite paranasale grave. Se descrie managementul cazurilor, respectiv cel mai eficient tratament. Rezultate: datorită manifestării în primul rând oftalmologice a bolii, copiii se prezintă de regulă la oftalmolog, acesta fiind cel care inițiază o strategie investigațională, precum și un tratament de debut. Odată cu diagnosticarea radioimagică a unei sinuzite paranasale, cel mai frecvent etmoidale în cazul copiilor, s-a luat în considerare drenajul focarului de infecție sinusal de către specialistul ORL. Toate intervențiile s-au efectuat prin metoda FESS, cu rezultate excelente. Concluzii: fiind vorba de multe ori de urgențe majore, cu pericol vital la copil, oftalmologul trebuie să fie în măsură să stabilească în timp util un diagnostic de probabilitate orientând copilul către consulturile paraclinice, interclinice (CT, ORL) competente în rezolvarea cazului.

## INTRODUCTION

Sino-orbital syndrome shows a rhino-neuro-ophthalmologic condition, simultaneously or successively, clinical and imagistic diagnosed and FESS (Functional Endoscopic Sinus Surgery) approached. It is a rhino-sino-orbital-ocular intricate pathology of different etiology (infectious, tumors, trauma etc.) with multiple forms of manifestation, firstly characterized by the prevalence of ophthalmologic clinical findings, presenting onwards a variability of different symptomatology. In the end it benefits mostly from oto-rhino-laryngological treatment.

The etiology can be structured into the following pathogenic groups:

1. Predisposed variations of development
2. Local or regional trauma
3. Thyroid determination
4. Inflammatory diseases
5. Infectious diseases
6. Tumor's origin of supra-, meso- and infra-structure
7. Complex (by the addition of those above)

The spread pathways are classified into:

- **direct**, in case of bony dehiscence
- **venous**, the orbital veins being nonvalvular or with a hypoplastic valvular system
- **arterial**, virtually of no significant importance and
- **lymphatic**, although the lymphatic system is poorly represented into the orbit.

The predisposed anatomic and functional conditions are:

- the existence of natural partitions (fissures, orifices and slits) which include nervous and vascular structures
- congenital dehiscence (some say that they are generally found in 37% of the population) or developed dehiscence of the orbital walls, respectively of the canalis opticus which allow direct contacts between the mucoperiosteum of the sinus and the orbital structures; similar alterations of the lateral wall of the sphenoidal sinus were described in approximately 6% of the cases (1,3)
- reduced thickness of the orbital-sinuses walls, eloquent example being lamina papyracea of the ethmoid
- orbital periosteum mainly non-adherent allows septic collections and hematoma to pass into the orbital

<sup>1</sup>Corresponding Author: Karin Horvath, Ophthalmology Clinic Târgu-Mureș, 26 Marton Aron street, 540082 Târgu-Mureș, Romania, e-mail: kuhorvath@gmail.com, tel +40- (0265) 26.21.22

ACTA MEDICA TRANSILVANICA March 2010; 2(1):158-160

## CLINICAL ASPECTS

- space (4)
  - the lack or the hypoplastic venous valvular system allow blood circulation in both ways, to respectively from the orbit
  - anastomosis between orbital venous system and
    - nasal veins
    - facial veins
    - lacrimal-nasal veins
    - venous system of the maxillary sinus
    - frontal veins
    - pterygoidian venous system
    - cavernous sinus
  - the lack of orbital lymphatic drainage
  - the construction in “closed box” of the orbit, bony pyramidal shape with a top represented by apex and a firm base formed by the orbital septum.
- The clinical forms can be classified into:
- with the affection of the orbital walls and the periorbital areas which include:
    - Nonsuppurating and suppurating orbital osteoperiostitis with anterior, medium and posterior localization
    - Orbital apex syndrome (Rolle)
    - Sphenoidal slit syndrome (Rochon Duvigneaud)
  - with the affection of the orbital content:
    - Anterior (preseptal) and posterior (postseptal) orbital cellulites
    - Serous and septic tendonitis
    - Myositis
    - Orbital vasculitis (granulomatosis Wegener)
    - Optic neuritis
  - special forms:
    - Inflammatory pseudotumors histopathologically divided into type I and II
    - Mucocele
    - Pyomucocele
    - Pneumosinus dilatans
    - Complex trauma

A topographic classification created by us, (2) which was particularly useful in the daily practice, divides the inflammatory sino-orbital syndrome into anterior, posterior and combined one.

**The Anterior Sino-orbital Syndrome** appears for example into a preseptal cellulitis along with a frontal, ethmoidal or maxillary sinusitis.

**The Posterior Sino-orbital Syndrome** appears into a postseptal orbital cellulitis, a phlegmon or retrobulbar orbital abscess, possibly being followed by a so called posterior sinusitis (posterior ethmoiditis, sphenoiditis).

**The Combined Sino-orbital Syndrome** blends together the signs of the first two, being relatively often found in severe cases of pansinusitis and wide orbital reactions with exophtalmus, affecting the orbital apex or the sphenoidal slit.

The Functional Endoscopic Sinus Surgery (FESS) aims at reestablishing the permeability of the nasal fossa, the drainage of the sinus infection, the elimination of some sinus deforming formations (mucocele, pyomucocele), as well as the microsurgical approach of some bordering pathologies, decompression of the orbit or of the optic nerve, the drainage of orbital suppurations, biopsies from retrobulbar or orbital apex formations.

### CASE PRESENTATION

The case-book record (see table 1) includes 8 children diagnosed at the Ophthalmology Clinic Tg-Mures. Following

the radioimagistic investigations made in emergency, the children were subjected to an endonasal surgical intervention of the sinus hotbed, respectively the drainage of an orbital subperiosteal collection where needed.

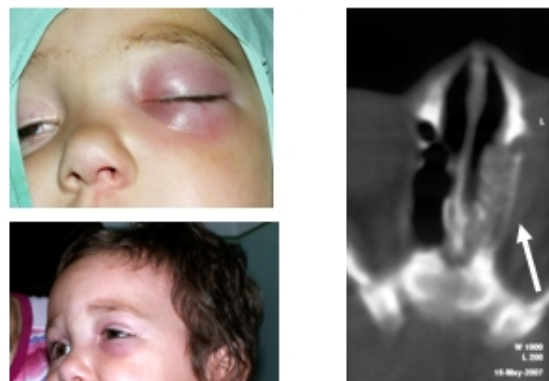
**Table1. Case-book record**

| No | Age (years) | Sex | Ophthalmologic dg  | ORL dg   | Treatment                            |
|----|-------------|-----|--|--|--------------------------------------|
| 1  | 3           | F   | Orbital cellulitis   | Ethmoiditis, Subperiosteal abscess                               | FESS                                 |
| 2  | 18          | F   | Orbital phlegmon   | Maxillary sinusitis Acute ethmoiditis                            | FESS                                 |
| 3  | 7           | M   | Retrobulbar optic neuritis<br>Right eye visual acuity light perception | Pansinusitis   | FESS<br>Visual acuity postop 0,25    |
| 4  | 12          | F   | Orbital phlegmon   | Pansinusitis   | FESS+lateral orbitotomy              |
| 5  | 10          | F   | Orbital phlegmon<br>Dacryoadenitis                                     | Pansinusitis   | FESS                                 |
| 6  | 11          | M   | Orbital phlegmon, palpebral phlegmon                                   | Pansinusitis   | FESS+ subperiosteal abscess drainage |
| 7  | 13          | F   | Profound papillary drusen<br>Cephalalgia, Epilepsy                     | Pneumosinus dilatans   | FESS                                 |
| 8  | 16          | F   | Fistulised dacryocystitis  | Fistulised abscessed ethmoiditis, Fistulised maxillary sinusitis | FESS ethmoid maxillary               |

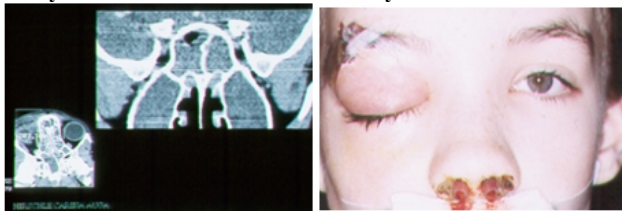
A typical example for the little child's pathology is presented in picture no. 1, where a quick recovery was reached by prompt measures of FESS drainage along with a vigorous antibiotherapy (see the aspect at 19 hours postoperative).

In some cases the FESS drainage of pansinusitis solves the issue of periorbital hotbed and partially the orbital phlegmon but the abscessed dacryoadenitis needs an external drainage. (Picture no. 2)

**Picture no. 1. Case1. Orbital cellulitis, subperiosteal abscess (CT), preoperative aspect (left upper image) and 19 hours postoperative aspect (left lower image)**

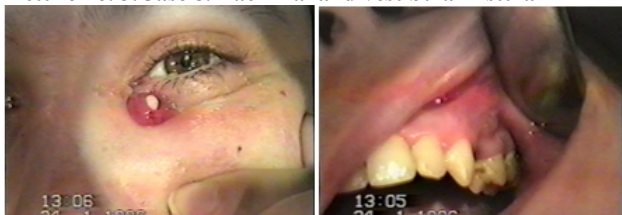

**Pictue no. 2. Case 5. Pansinusitis (CT), orbital phlegmon, dacryoadenitis with lateral orbitotomy**



Regarding a 16 years-old girl, case 8, the tendency of abscess of sinusitis manifests itself in the ophthalmological as well as in the oral maxillary area. So, we can observe a fistulised dacryocystitis, as well as a vestibular fistula (Figure 3)

**Picture no. 3. Case 8. Lacrimal and vestibular fistula**



### CONCLUSIONS

As an interdisciplinary pathology which is firstly situated at the border between ophthalmology and otorhinolaryngology and secondly oral-maxillo-facial and neurology, respectively neurosurgery, sino-orbital syndrome diseases are more and more present into daily practice, producing numerous question marks regarding the case's affiliation, the indication and the moment of surgical intervention. Unfortunately we still meet a "bird" tendency of the patient from one department to another in order to escape the responsibility of hospitalizing and treating such a case, losing precious time which would be very useful in solving the case. Regardless the moment of presentation to the doctor, the evolutive state of disease or the first consulted specialist, the situation is indeed an emergency and not an insignificant one but always a major one.

The paper emphasizes the importance of the ophthalmologist in initiating an early investigational and therapeutical direction for the life of the little patient depends on his prompt attitude.

### REFERENCES

1. Eustis H, Mafee M, Walton C, Mondonca J. MR imaging and CT of orbital infections and complications in acute rhinosinusitis. *Radiol Clin North Am*, 1998;36(6):1165-1183.
2. Horvath K, Mühlfay Gh. Sindromul sino-orbital. Univesity Press Tg-Mureş, 2008:53-54.
3. Stammberger H., Hawke M. Essentials of Functional Endoscopic Sinus Surgery. Mosby, 1993:25-29.
4. Woo K.I., Kim Y.D.: Subperiosteal hematoma of the orbit associated with sinusitis. *Korean J Ophthalmol*, 1997;11(2):118-122.